

Interventional Nephrology: Physical Examination as a Tool for Surveillance for the Hemodialysis Arteriovenous Access

Loay Salman* and Gerald Beathard[†]

Summary

The prospective recognition of stenosis affecting dialysis vascular access and its prospective treatment is important in the management of the hemodialysis patient. Surveillance by physical examination is easily learned, easily performed, quickly done, and economical. In addition, it has a level of accuracy and reliability equivalent to other approaches that require special instrumentation. Physical examination should be part of any education to all hemodialysis care givers. This review presents the basic principles of physical examination of the hemodialysis vascular access and discusses the evidence behind its value.

Clin J Am Soc Nephrol 8: 1220–1227, 2013. doi: 10.2215/CJN.00740113

Introduction

Physical examination (PE) of the arteriovenous (AV) access is of established clinical importance. The National Kidney Foundation Kidney Disease Outcomes Quality Initiative (KDOQI) guidelines on vascular access (1) list techniques that are recognized as being of value for AV access surveillance for both AV grafts (AVGs) and AV fistulas (AVFs) and divides into preferred and acceptable categories. PE is listed as preferred for an AVF and acceptable for an AVG. The KDOQI guidelines recommend that PE of the AV access be performed by a qualified individual on regular basis (at least monthly) when used for surveillance.

The primary purpose of this examination is to detect vascular stenosis or other abnormalities that might lead to dysfunction. This can be done with levels of accuracy that are quite acceptable (2–15). In contrast to other approaches to AV access surveillance, it is simple to perform and does not require additional machines, regular calibrations, additional cost, or additional staff. In addition, unlike other surveillance techniques that detect stenosis prospectively, PE can also detect other problems that can adversely affect the AV access. For these reasons, plus the fact that it is easily learned (16), PE should be taught to all hemodialysis care givers, including nephrology fellows, and should be performed on a regular basis on all hemodialysis patients (15).

Basic Principles

As with PE applied to other areas of medical practice, the cornerstones of PE of the AV access are inspection, palpation, and auscultation. Table 1 summarizes the basic components of PE as they have become established (4,17,18).

Inspection

A great deal of useful information can be gained by a careful inspection of the patient's AV access, the

access extremity, and adjacent anatomy. Access inspection should include an evaluation of its diameter, usable length (portion available for cannulation), and the presence of any obvious side branches. In addition, there is a special maneuver that should be performed—the arm elevation test. Inspection should include the ipsilateral extremity, shoulder, chest, breast, neck, and face. It should also include a comparison with the opposite extremity.

Special attention should be given to the presence of any signs of infection. AV access–associated infection may be either superficial or deep (Figure 1). Superficial infections are generally related to a cannulation site and do not involve the access itself. On PE, they are characterized as small pustular lesions without other signs to suggest infection. Deep infections generally have the classic combination of signs of infectious inflammation, including swelling, erythema, tenderness, and purulence (Figure 1). The erythema is generally localized and spreads in a circumferential manner so that it extends beyond the skin immediately overlying the access.

The presence of edema in the extremity ipsilateral to the access is almost always indicative of the presence of central venous stenosis (Figure 2). The extent of the edema can help in predicting the location of the central venous stenosis. If the edema involves only the arm, this suggests that the stenosis is at the level of the subclavian vein. If the edema includes the ipsilateral chest, breast, and/or face, the stenosis is most likely at the level of the brachiocephalic vein. Edema that includes both sides (chest, breasts, shoulders, face) is suggestive of superior vena cava stenosis.

Any scars on the chest and neck should be evaluated because they might indicate the sites of previous temporary or tunneled hemodialysis catheters (Figure 2). In addition, attention should be given to the presence of a cardiovascular implantable electronic device on the chest wall. These devices are frequently associated with

*Division of Nephrology, University of Miami Miller School of Medicine, Miami, Florida; and [†]DaVita, Austin, Texas

Correspondence:

Dr. Loay Salman, Division of Nephrology, University of Miami Miller School of Medicine, 1400 NW 12th Avenue, Miami, FL 33136. Email: l.salman@miami.edu

Table 1. Clinical features of basic lesions				
	Normal	Inflow Stenosis	Outflow Stenosis	Central Vein Stenosis
Clinical abnormality	None	Difficult cannulation Poor flow Negative arterial pressure	Prolonged bleeding Poor flow High venous pressure	Difficult cannulation \pm Poor flow \pm Increased venous pressure \pm
Physical examination				
Inspection	Normal appearance	Poorly defined \pm	Distended Aneurysmal \pm Does not collapse with arm elevation	Swollen arm, etc Collateral veins Does not collapse with arm elevation
Palpation				
Pulse	Soft, easily compressible	Hypo-pulsatile Poor pulse augmentation	Hyperpulsatile	Variable
Thrill	Continuous	Discontinuous Decreased	Discontinuous Accentuated at site of lesion	Variable May be present beneath clavicle
Auscultation				
Bruit	Continuous	Discontinuous Decreased	Discontinuous Accentuated at site of lesion	Variable May be present beneath clavicle

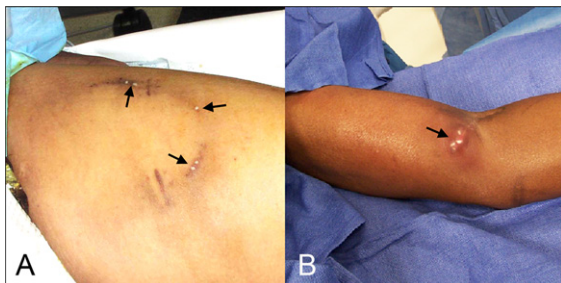


Figure 1. | Arteriovenous access infection. (A) Superficial. Arrows indicate infected cannulation sites. (B) Deep infection. Note pustules and swelling.

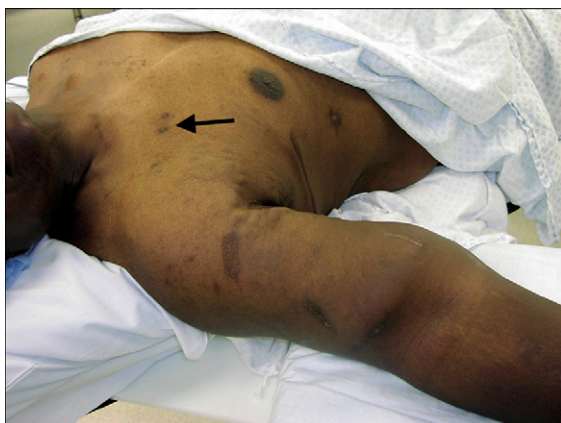

Figure 2. | Central vein stenosis. Note markedly swollen right arm. Arrow indicates old catheter sites.

central vein stenosis. The presence of collateral veins in the arm or chest should be noted (Figure 3) because these are frequently indicative of downstream stenosis.

Aneurysms and pseudoaneurysms (Figure 4), if present, should be carefully examined. The overlying skin should be examined for evidence of marked thinning, depigmentation, tightening of the overlying skin, ulceration, or spontaneous bleeding. If the skin is tissue-paper thin and cannot be pinched between the index finger and thumb, it has advanced to a dangerous degree.

PE can also detect evidence of vascular steal syndrome leading to hand ischemia (Figure 5). In the mildest cases, the affected hand is pale or cyanotic in appearance compared with the opposite side. In more severe cases, evidence of ischemic changes in the skin, especially at the fingertips, may be present.

Arm Elevation Test. This test should be included in the inspection of the AVF. Unfortunately, this maneuver does not work with an AVG because of the higher level of pressure that characterizes this type of access. In the patient with an AVF, the access is generally distended when the arm is dependent due to the effects of gravity (Figure 6A). If the arm is then elevated to a level above that of the heart, the AVF should collapse (Figure 6B) (4,17,18). Even if the patient has a large dilated AVF, it should become flaccid. However, if a venous stenosis is present, only the portion of the AVF proximal to the lesion will collapse while that portion distal to the site will remain distended. One can conclude with a reasonable degree of confidence that the outflow of the access is normal if the patient’s AVF collapses when the arm is elevated.

Palpation

Inspection of the AV access should be followed by palpation. This includes two very important aspects of the PE—the detection of any thrill that might be present and

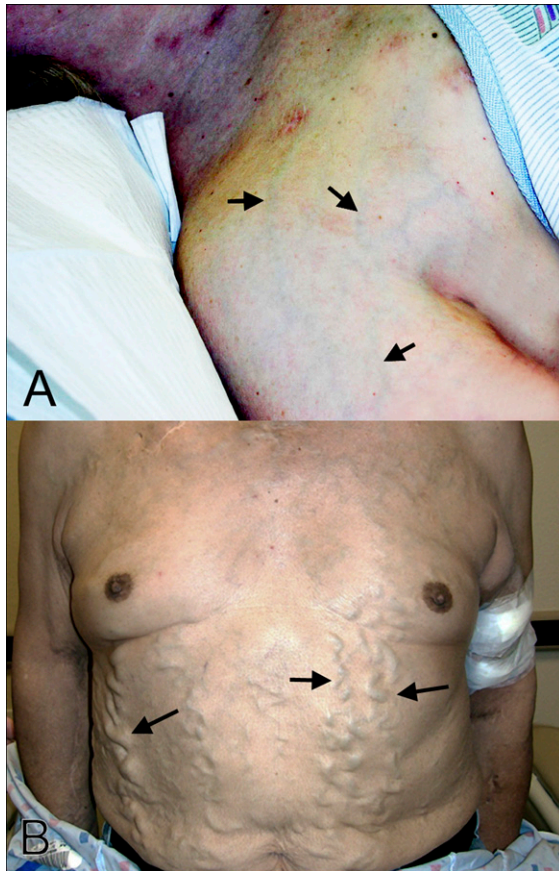


Figure 3. | Patients with central vein stenosis. (A) Early, subcutaneous collaterals (arrows). (B) Late, large collaterals over thorax and abdomen (arrows).

evaluation of the pulse. These are of significant value in identifying the cause of the dysfunction (4,17,18). In addition, two special maneuvers should be performed—evaluation of pulse augmentation and the sequential occlusion test.

Pulse. Normally, the AV access is easily compressible with very little pulse. In general, a pulsatile AV access is an adverse finding, and it is indicative of a downstream lesion (Figure 1). The degree of hyperpulsatility that is present is proportional to the severity of the stenosis. An unusually weak pulse (hypopulsatile access) or “flat access” suggests the presence of a stenotic lesion in the inflow side of the access. The pulse may be best appreciated using the fingertips (Figure 7).

Thrill. A thrill is a palpable vibration (“buzz”). It is related to flow; when present, it indicates that there is flow within the access. The examination of an access can reveal two different types of thrill—a diffuse background thrill and a localized accentuated thrill. The presence of a soft, continuous (systolic and diastolic), diffuse background thrill palpable over the course of the access, either an AVF or an AVG, is normal. This is most obvious at the venous anastomosis.

A stenotic lesion creates a localized area of turbulent flow within the vessel. As the lesion develops with progressively increasing resistance to flow, the thrill becomes shortened and eventually loses its diastolic component. The entire course of the access drainage should be examined for the presence of an abnormal thrill. With subclavian or cephalic arch stenosis, a

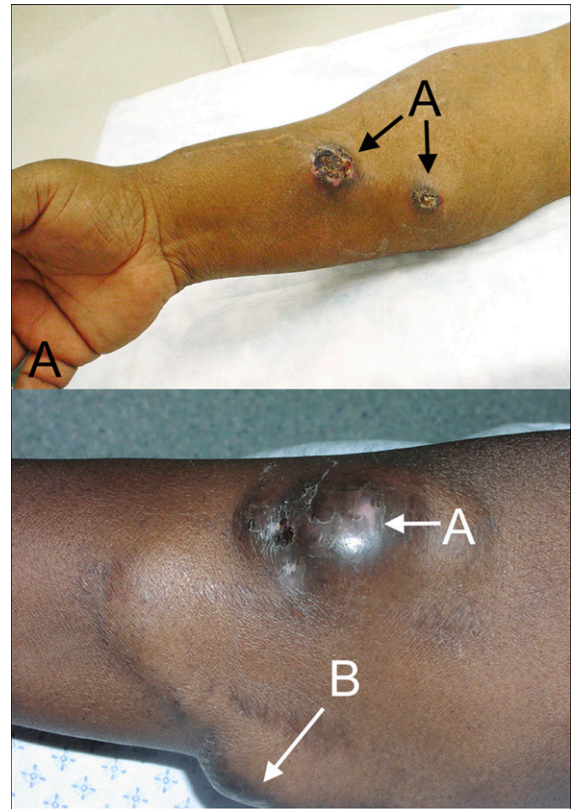


Figure 4. | Aneurysms and pseudoaneurysms of hemodialysis arteriovenous access. (A) Arteriovenous fistula with aneurysms with ulceration (arrows; depigmentation with early skin break-down). (B) Arteriovenous graft with large pseudoaneurysms (fusiform pseudoaneurysm).

thrill can often be detected below the clavicle. The absence of a thrill indicates a lack of flow. This finding, along with the absence of any pulse, is characteristic of a thrombosed or “clotted” access. The thrill may be best evaluated by using the palm of the hand (Figure 8).

Pulse Augmentation Test. The assessment of pulse augmentation evaluates the inflow portion of the AV access (4,17,18). This test is performed by occluding the access several centimeters above the arterial anastomosis with one hand while evaluating the intensity of the pulse with the other. This test is based upon the fact that if the access is completely occluded some distance from the arterial anastomosis, the normally soft pulse will become augmented (Figure 9). The degree of this increase in pulse intensity is directly proportional to the quality of the access inflow. If there are problems anywhere within the arterial system from the anastomosis upward, it will affect the degree to which the pulse is augmented. Although this works better for AVF evaluation, it also serves reasonably well in the evaluation of an AVG.

If the pulse within the access happens to already be increased due to the presence of a venous downstream stenosis, the test is still useful. If the hyperpulsatile access does not augment with occlusion, it suggests that the stenosis is essentially equivalent to complete obstruction. If it augments 50%, then it suggests 50% occlusion for the stenosis.

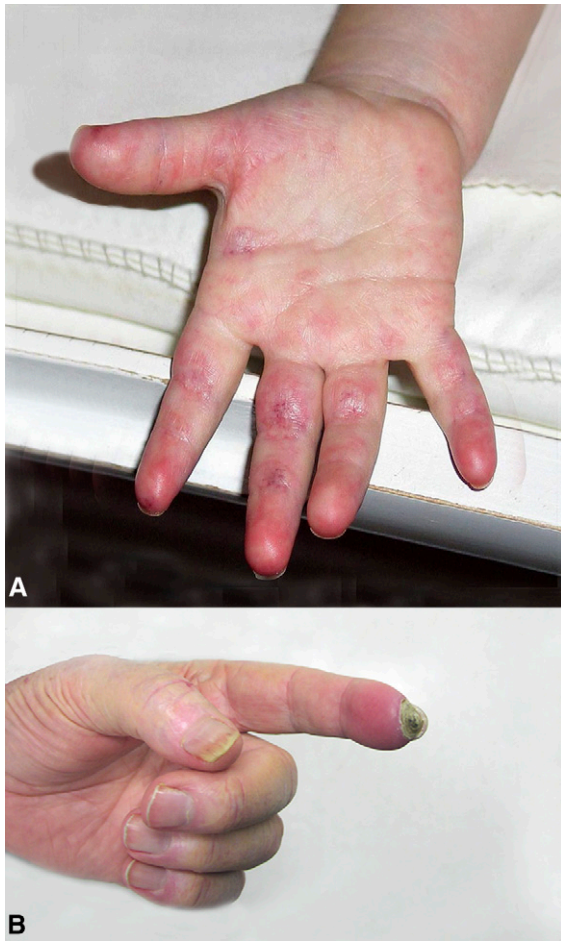


Figure 5. | Hand ischemia due to dialysis access steal syndrome. (A) Early chronic ischemia of hand without tissue loss (hand was cold). (B) Tissue loss at the fingertip is evident (dry gangrene).

For ease of communication and documentation, it is advantageous to grade the degree of pulse augmentation achieved by access occlusion on a scale of 1–10, with 10 of 10 being normal.

Sequential Occlusion Test. This test is similar to the pulse augmentation test except in this instance, the focus is upon the disappearance of the thrill with occlusion. Its purpose is to detect side branches coming off of an AVF (4,17,18). Frequently, the side branch is visible and may have already been detected by inspection of the AV access.

This test is dependent upon the relationship between the thrill and access flow. It is conducted by occluding the AVF a short distance above the AVF with one hand while feeling for the thrill with the other (Figure 10). The thrill that is palpable over the arterial anastomosis indicating the presence of flow disappears when the downstream AVF is manually occluded causing flow to stop. As long as the main channel can be identified for occlusion, the entire length of the vein can be evaluated by moving the point of occlusion progressively upward. If at any point, the thrill does not disappear, an outflow channel (side branch) is present below the point of occlusion.

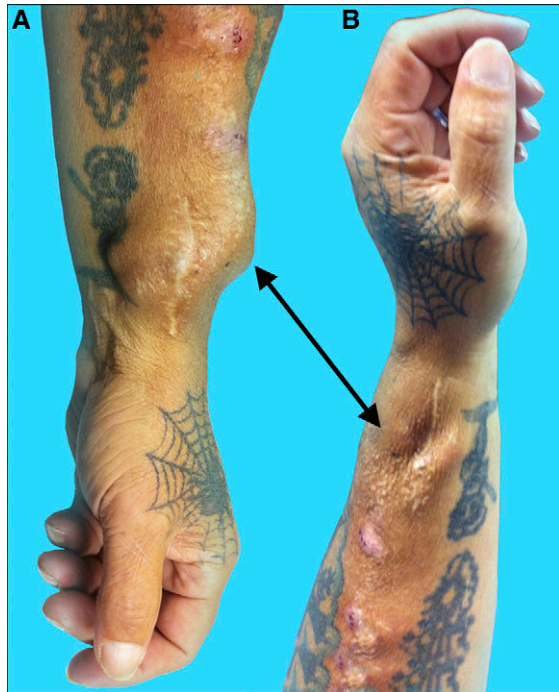

Figure 6. | Arm elevation test. (A) When the arm is dependent, the fistula is distended (arrow). (B) When the arm is elevated, the fistula is collapsed (arrow).

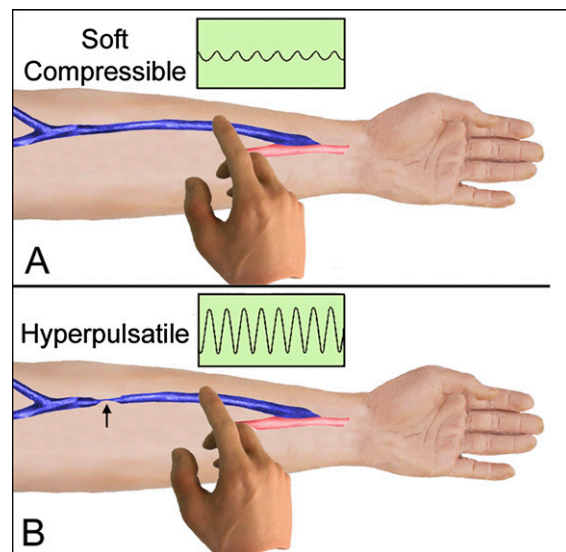


Figure 7. | Palpation of pulse with fingertips. (A) Normal pulse is soft and compressible. (B) With stenosis downstream, the pulse is increased.

Auscultation

Palpation of the AV access should be followed by auscultation. This involves listening for and recognizing changes in the normal bruit and the detection of abnormal ones.

Bruit. The bruit is the auditory manifestation of a thrill and has the same basic implications (Figure 11). As with the thrill,

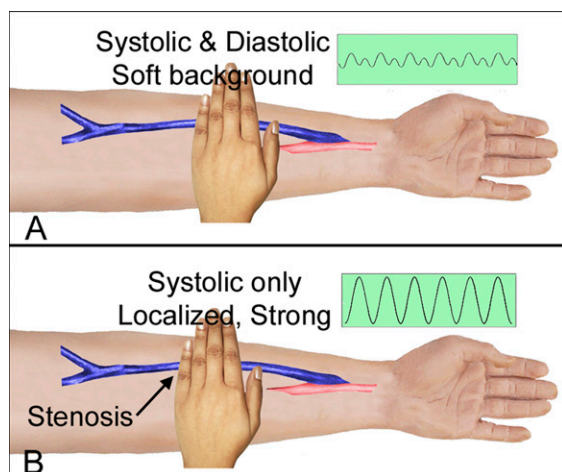


Figure 8. | Palpation of thrill with palm of hand. (A) Normal thrill is soft and continuous, systolic, and diastolic. (B) With stenosis, the thrill is increased, localized to area of lesion, and systolic only.

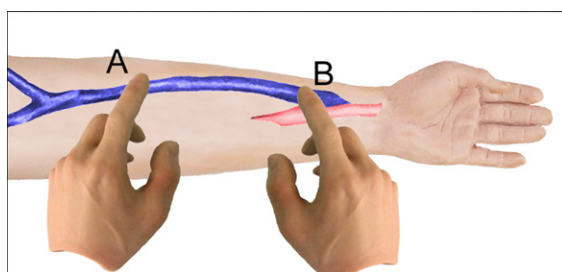


Figure 9. | Pulse augmentation test. (A) The arteriovenous fistula is occluded. (B) The pulse is assessed for augmentation.

there are two types of bruit that can be heard—the normal background bruit and that which is associated with stenosis. The background bruit has both systolic and diastolic components and is a low-pitched, soft rumbling, machinery-like sound.

Increasing resistance from a progressively stenotic lesion will result in the progressive loss of the diastolic component and with this the pitch becomes progressively higher. The entire course of the access drainage, including the area beneath the clavicle, should be examined for the presence of an abnormal bruit.

PE Characteristics of Specific Lesions

Using the basic principles as outlined, there are a number of specific lesions that can be identified and localized using PE. It should be noted that in general, these descriptions relate to lesions that are sharply defined (severe). Lesser ones will produce changes that are less dramatic.

Venous Stenosis

The stenotic site is characterized by turbulent blood flow and increased resistance to flow. As a result, a palpable, localized thrill is palpable and a bruit is audible. As the lesion becomes more severe, the increasing resistance will eventually exceed the diastolic pressure. Then the thrill and bruit will only be systolic. The pitch of the bruit also rises as the degree

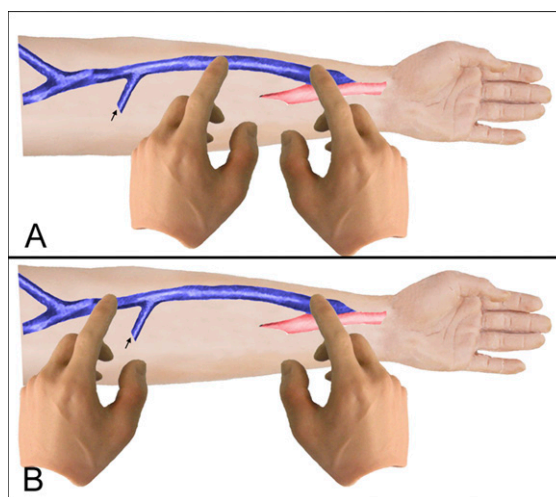


Figure 10. | Sequential occlusion test. (A) With occlusion at this point, the thrill will disappear. (B) With occlusion at this point, the thrill will persist because of the side branch.

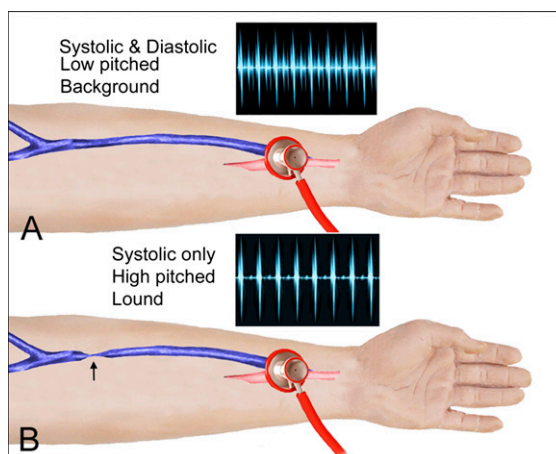


Figure 11. | Listening to bruit. (A) In the normal situation, the bruit is low pitched and with systolic and diastolic components. (B) With a stenotic lesion, the bruit becomes high in pitch and has only a systolic component.

of stenosis advances and the velocity of flow increases. The AVF or vein upstream from a stenotic lesion will become distended and hyperpulsatile due to the increased resistance (Figure 12).

Central Vein Stenosis. First, it is important to realize that not all central venous lesions are hemodynamically significant (19–24). The presence of a swollen ipsilateral extremity is indicative of a significant lesion (Figure 13), and at times this can be massive. In addition, subcutaneous collateral veins over the arm and chest are frequently evident. Although the access is often pulsatile with central vein stenosis, it is generally not as pulsatile as one expects to see with a more peripheral lesion. Often, especially in thin-chested individuals with a subclavian or cephalic arch lesion, a localized thrill can be felt over the anterior chest just below the clavicle, and a localized bruit is also frequently evident.

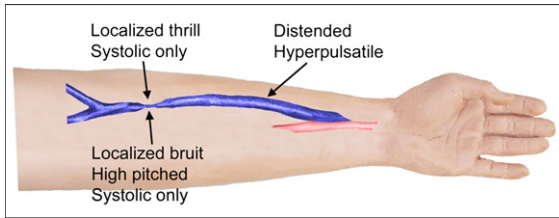


Figure 12. | Physical examination findings of venous stenosis.

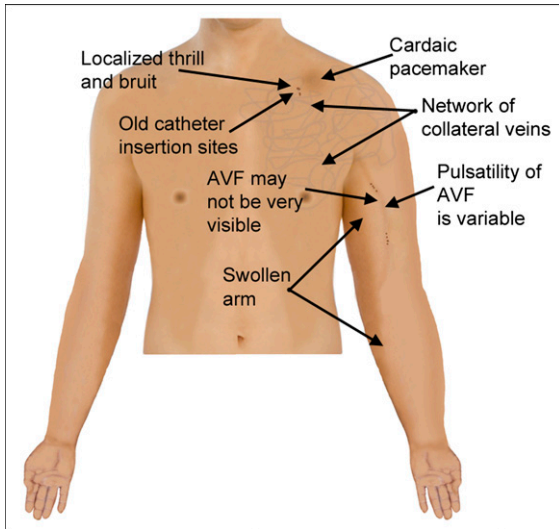


Figure 13. | Physical findings of central vein stenosis. AVF, arteriovenous fistula.

Inflow Stenosis

An assessment of augmentation will identify the presence of an inflow lesion, a designation that includes lesions within the feeding artery, the arterial anastomosis, and the juxta-anastomotic portion of the AVF (not actually part of the arterial circuit). The former two of these cannot be easily distinguished by PE; however, juxta-anastomotic stenosis has unique PE findings.

Juxta-Anastomotic Stenosis. Juxta-anastomotic stenosis is defined as stenosis that occurs within that portion of the AVF that is immediately adjacent, within 2–3 cm, to the arterial anastomosis (Figure 14). The effect of the lesion is to obstruct AVF inflow. This lesion can be easily diagnosed by PE of the anastomosis and distal vein (4,17,18). Normally, a very prominent continuous thrill is present at the anastomosis and there is very little if any pulse. With this lesion, the thrill is present only in systole and the pulse is forceful at the anastomosis, but goes away rather abruptly as the examining finger moves up the vein and the site of stenosis is encountered. Above this level, the pulse is very weak and may be difficult to detect. The stenosis itself can frequently be felt as an abrupt diminution in the size of the vein.

Accessory Veins

The sequential occlusion test can be used to identify the presence of an accessory vein that is not already obvious by

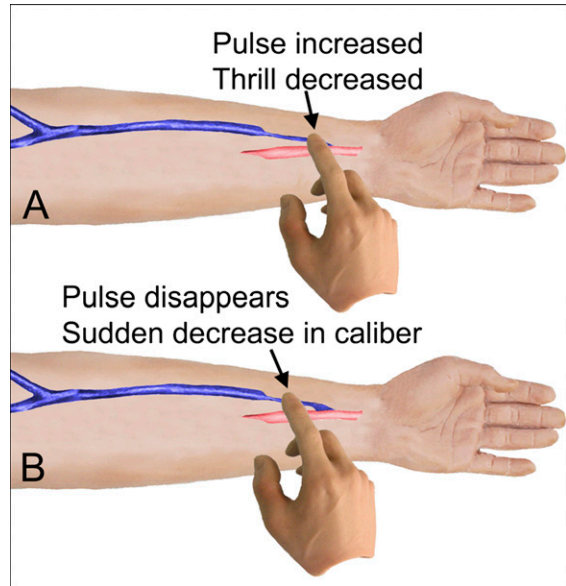


Figure 14. | Physical findings of juxta-anastomotic stenosis.

visual examination (Figure 10). The presence of an accessory vein is essentially limited to the forearm. It is generally a branch of the cephalic and represents normal anatomy. Collateral veins can appear with downstream stenosis and can be confused with this entity. However, collaterals are pathologic; the presence of a stenotic lesion should alert the examiner to their etiology.

Accuracy of PE

The goal of surveillance is to prospectively detect stenosis that affects the AV access. In order to validate any of the proposed techniques, its accuracy compared with angiography, the gold standard, must be assessed. Several publications have attempted to do this. In 1992, it was reported (2) that in a series of 328 AVGs, a 91.7% incidence of significant (> 50%) venous stenosis was detected by angiography that was performed after a screening PE. In his 1994 review of techniques for the prospective detection of venous stenosis, Depner (25) directed attention to the importance of this approach. In 1996, Trerotola *et al.* (3) concluded that PE was a good screening test for ruling out the low blood flow associated with impending access AVG failure after comparing the various methods advocated for screening for venous stenosis. Also in 1996, Safa *et al.* (26) concluded that an abnormal PE finding was the most common indicator of AVG dysfunction.

In 2000, Mishler *et al.* (5) reported a study in which PE in 59 consecutive patients was compared with angiography. They demonstrated that their examination was accurate in predicting stenoses in 91% of the patients. In 2006, Choi *et al.* (10) published a report dealing with the accuracy of PE in the detection of vascular access dysfunction in 48 patients with an AVF. In their study, PE was performed 1 month after the creation of the access. Angiography was then performed and compared with findings of the PE. Twenty of the 48 patients demonstrated a normal PE, and only 1 of

these patients was found to have a problem by angiography ($P<0.001$). Of the 28 patients with an abnormal PE, 70% were found to have an abnormal angiogram ($P<0.001$).

In 2007, Asif *et al.* (11) reported a prospective study in which 142 consecutive patients with AVF dysfunction were evaluated to examine the accuracy of PE in the detection of stenotic lesions compared with angiography. The images were reviewed by an independent interventionalist with expertise in endovascular dialysis access procedures who determined the final diagnosis. The reviewer was blinded to the PE. Cohen's κ was used as a measurement of the level of agreement beyond chance between the diagnosis made by PE and angiography. In this study, the investigators found that there was a strong agreement between PE and the angiography in the diagnosis of outflow stenosis (89.4% agreement; $\kappa=0.78$) and inflow stenosis (79.6% agreement; $\kappa=0.55$). The sensitivity and specificity for the outflow and inflow stenosis were 92%, 86%, 85%, and 71%, respectively. There was a strong agreement beyond chance regarding the diagnosis of coexisting inflow-outflow lesions between the PE and angiography (79% agreement; $\kappa=0.54$). The PE for central vein stenosis showed a sensitivity of 13% and a specificity of 99%, with a κ value of only 0.17 indicating a weak agreement between the two modalities. Stenosis within the body of the AVF had a sensitivity of 40% and a specificity of 84% for the PE, with a κ value of 0.18 demonstrating weak agreement. A comparison of data derived from forearm and upper arm AVFs revealed no significant difference in the level of agreement. The κ values for forearm and upper AVFs were 0.77 and 0.79, respectively. It should be noted that the patients with a central lesion were asymptomatic in this study.

In a subsequent study from the same group (12), PE of AVGs was found to be a good indicator of access pathology, but not as good as they had reported for AVFs. There was good agreement between PE and angiography in the diagnosis of vein-graft anastomotic stenosis ($\kappa=0.52$). The sensitivity and specificity for this lesion were 57% and 89%, respectively. There was a moderate agreement beyond chance regarding the diagnosis of intragraft ($\kappa=0.43$) and inflow stenoses ($\kappa=0.40$). The sensitivity and specificity for the intragraft and inflow stenosis were 100%, 73%, 33%, and 73%, respectively. The PE for central vein stenosis showed a sensitivity of 16% and specificity of 100%. A κ value of 0.18 indicated only a slight agreement between the PE and angiography. Again, the patients in this study with a central lesion were asymptomatic.

In another study in which PE was compared with Doppler ultrasonography, Campos *et al.* (13) evaluated 84 AVF patients (52% distal, 48% proximal). Abnormalities of pulse and thrill were used as the diagnostic tools for the detection of stenosis using the PE. Fifty-six patients (66%) were considered positive for the presence of stenosis by PE. According to Doppler ultrasonography, 50 patients (59%) were considered positive for the presence of stenosis (a reduction in internal diameter $>50\%$). Calculations for sensitivity, specificity, positive predictive value, and negative predictive value were 96%, 76%, 86%, and 93%, respectively. Unfortunately, the location of the lesions was not specified in the report.

The accuracy of PE was further demonstrated in a study by Tessitore *et al.* (14) conducted in 119 unselected hemodialysis patients with mature AVFs. Of these, 102 were distal AVFs

and 17 were proximal. In the study, PE-derived static venous pressure (VAPR) and access blood flow (Qa) were performed followed by an angiographic evaluation of the access (other methods of access surveillance were performed but only these two are listed here for comparison with PE). Angiography identified 59 stenotic AVFs: 43 stenoses were inflow stenosis, 12 were outflow stenosis, and 4 were located at both sites. PE and Qa were the best tests for detecting inflow stenosis. PE had an accuracy, sensitivity, specificity, and κ value of 74%, 70%, 76%, and 0.46, respectively. A Qa of <650 ml/min had values of 80%, 65%, 89%, and 0.57, respectively. PE and VAPR >0.5 were the best tests for outflow stenosis. PE had an accuracy, sensitivity, specificity, and κ value of 91%, 75%, 93%, and 0.63, respectively. These values for VAPR >0.5 were 85%, 94%, 84%, and 0.52, respectively. The authors concluded that a moderate to excellent accuracy in detecting and locating AVF stenosis could be achieved at the bedside by combining two tests—PE and Qa measurement. Determination of VAPR was discounted because it is more difficult to do.

Reproducibility of PE

Tessitore *et al.* (14) examined inter-rater agreement for PE and found that it was only fair to moderate. The operator dependence of PE only appeared to concern inflow stenosis, with the most experienced rater performing better than the less experienced, not outflow stenosis. They felt that the observed discrepancy was most likely due to the fact that the elements most frequently used to identify outflow stenosis are less subjective than those generally used to identify inflow stenosis. However, it was pointed out that their findings indicated that the necessary PE skills can be taught and improved with experience in access monitoring.

These observations support those of Leon and Asif (16) who found that after receiving 1 month of training in PE, both didactic and hands-on, a nephrology fellow could detect AVF pathology as well as an experienced interventionalist.

Disclosures

None.

References

1. National Kidney Foundation: KDOQI Clinical Practice Guidelines. Available at: http://www.kidney.org/professionals/Kdoqi/guideline_upHD_PD_VA/va_guide4.htm. Accessed January 4, 2013
2. Beathard GA: Physical examination of AV grafts. *Semin Dial* 5: 74, 1992
3. Trerotola SO, Scheel PJ Jr, Powe NR, Prescott C, Feeley N, He J, Watson A: Screening for dialysis access graft malfunction: Comparison of physical examination with US. *J Vasc Interv Radiol* 7: 15–20, 1996
4. Beathard GA: Physical examination of the dialysis vascular access. *Semin Dial* 11: 231–236, 1998
5. Mishler R, Schon D, Hubert B, Nissenon A: Development and usefulness of a physical examination toll to diagnose vascular access dysfunction [Abstract]. *J Am Soc Nephrol* 11: 190A, 2000
6. Agarwal R, McDougal G: Buzz in the axilla: A new physical sign in hemodialysis forearm graft evaluation. *Am J Kidney Dis* 38: 853–857, 2001
7. Beathard G: *Physical Examination: The Forgotten Tool*, Philadelphia, Lippincott Williams & Wilkins, 2002
8. Trerotola SO, Ponce P, Stavropoulos SW, Clark TW, Tuite CM, Mondschein JI, Shlansky-Goldberg R, Freiman DB, Patel AA, Soulen MC, Cohen R, Wasserstein A, Chittams JL: Physical examination versus normalized pressure ratio for predicting

- outcomes of hemodialysis access interventions. *J Vasc Interv Radiol* 14: 1387–1394, 2003
9. Asif A, Gadalean FN, Merrill D, Cherla G, Cipleu CD, Epstein DL, Roth D: Inflow stenosis in arteriovenous fistulas and grafts: A multicenter, prospective study. *Kidney Int* 67: 1986–1992, 2005
 10. Choi JR, Kim YS, Yoon SA, Won YD, Son YS, Song WJ, Song HC, Chang YS, Bang BK, Kim YO: Accuracy of physical examination in the detection of arteriovenous fistula dysfunction. *Korean J Nephrol* 25: 797, 2006
 11. Asif A, Leon C, Orozco-Vargas LC, Krishnamurthy G, Choi KL, Mercado C, Merrill D, Thomas I, Salman L, Artikov S, Bourgoignie JJ: Accuracy of physical examination in the detection of arteriovenous fistula stenosis. *Clin J Am Soc Nephrol* 2: 1191–1194, 2007
 12. Leon C, Orozco-Vargas LC, Krishnamurthy G, Choi KL, Mercado C, Merrill D, Thomas I, Salman L, Artikov S, Bourgoignie JJ, Asif A: Accuracy of physical examination in the detection of arteriovenous graft stenosis. *Semin Dial* 21: 85–88, 2008
 13. Campos RP, Chula DC, Perreto S, Riella MC, do Nascimento MM: Accuracy of physical examination and intra-access pressure in the detection of stenosis in hemodialysis arteriovenous fistula. *Semin Dial* 21: 269–273, 2008
 14. Tessitore N, Bedogna V, Melilli E, Millardi D, Mansueto G, Lipari G, Mantovani W, Baggio E, Poli A, Lupo A: In search of an optimal bedside screening program for arteriovenous fistula stenosis. *Clin J Am Soc Nephrol* 6: 819–826, 2011
 15. Coentrão L, Faria B, Pestana M: Physical examination of dysfunctional arteriovenous fistulae by non-interventionalists: A skill worth teaching. *Nephrol Dial Transplant* 27: 1993–1996, 2012
 16. Leon C, Asif A: Physical examination of arteriovenous fistulae by a renal fellow: Does it compare favorably to an experienced interventionalist? *Semin Dial* 21: 557–560, 2008
 17. Beathard GA: An algorithm for the physical examination of early fistula failure. *Semin Dial* 18: 331–335, 2005
 18. Beathard G: *Physical Examination of the Hemodialysis Access*, New York, McGraw Hill, 2012
 19. Besarab A, Sullivan KL, Ross RP, Moritz MJ: Utility of intra-access pressure monitoring in detecting and correcting venous outlet stenoses prior to thrombosis. *Kidney Int* 47: 1364–1373, 1995
 20. Beathard GA: Percutaneous angioplasty for the treatment of venous stenosis: A nephrologist's view. *Semin Dial* 8: 166–170, 1995
 21. Schwab SJ, Raymond JR, Saeed M, Newman GE, Dennis PA, Bollinger RR: Prevention of hemodialysis fistula thrombosis. Early detection of venous stenoses. *Kidney Int* 36: 707–711, 1989
 22. Tuka V, Slavikova M, Krupickova Z, Mokrejsova M, Chytilova E, Malik J: Short-term outcomes of borderline stenoses in vascular accesses with PTFE grafts. *Nephrol Dial Transplant* 24: 3193–3197, 2009
 23. Levit RD, Cohen RM, Kwak A, Shlansky-Goldberg RD, Clark TW, Patel AA, Stavropoulos SW, Mondschein JJ, Solomon JA, Tuite CM, Trerotola SO: Asymptomatic central venous stenosis in hemodialysis patients. *Radiology* 238: 1051–1056, 2006
 24. Renaud CJ, Francois M, Nony A, Fodil-Cherif M, Turmel-Rodrigues L: Comparative outcomes of treated symptomatic versus non-treated asymptomatic high-grade central vein stenoses in the outflow of predominantly dialysis fistulas. *Nephrol Dial Transplant* 27: 1631–1638, 2012
 25. Depner TA: Techniques for prospective detection of venous stenosis. *Adv Ren Replace Ther* 1: 119–130, 1994
 26. Safa AA, Valji K, Roberts AC, Ziegler TW, Hye RJ, Oglevie SB: Detection and treatment of dysfunctional hemodialysis access grafts: Effect of a surveillance program on graft patency and the incidence of thrombosis. *Radiology* 199: 653–657, 1996

Published online ahead of print. Publication date available at www.cjasn.org.

Present Address: Dr. Gerald A. Beathard, University of Texas Medical Branch, Houston, Texas.